



ImmunoQuery

Quick, Confident Diagnosis.

Jasmine Tsai 蔡雅莉

Account Manager

0905129301

j.tsai@elsevier.com

ImmunoQuery

由決定性的專家經驗 及實證基礎所構成的 ImmunoQuery，
是免疫組織化學最可靠的 決策支援系統。

超過**150**萬筆診斷結果，協助您做出正確診斷

- * 1,537,212 個病例
- * 42,642 個抗體組合
- * 2,954 個抗體
- * 2,029 個診斷

ImmunoQuery

尋找可用抗體

〔建立診斷面板〕功能，可一次查詢最多三項的鑑別診斷，幫助您找出可確認診斷的抗體。

Modify and Save a Suggested Panel

取得鑑別診斷列表

〔建立抗體面板〕功能，可一次顯示最多三種抗體應，幫助您做出鑑別診斷；並且當得到相似的染色結果時提供其他的診斷決策。

分析結果 Analyze Results 從文獻的實證證據進一步證實您的抗體染色結果。

了解診斷內容

檢視屬於您的診斷的完整免疫組織化學資料，包括全部進行檢測抗體的陽性百分比、染色結果式樣、以及所有參考文獻列表（含摘要連結）。

Learn about a Diagnosis Group

了解抗體資訊

了解抗體的選殖株、生產公司、能利用該抗體染色進行診斷的優先族群、以及所有參考文獻列表（含摘要連結）。

Learn about an Antibody

Feature Highlights

1. 標靶專一導向的化學治療

為標靶專一導向的化學治療提供預後免疫組織化學標誌的新反應結果。

2. 更強大的鑑別診斷面板

在最常用的鑑別診斷面板中增加更多的新抗體與反應結果。

3. 重要抗體資訊

- ◆ STAT6：單發性纖維瘤 (Solitary Fibrous Tumor)
- ◆ TLE1：滑膜肉瘤 (Synovial Sarcoma)
- ◆ GATA3：乳癌 (Breast Carcinoma)、泌尿上皮細胞癌 (Urothelial Carcinoma)
- ◆ Glypican-3：肝細胞癌 (Hepatocellular Carcinoma)
- ◆ p40：鱗狀上皮細胞癌 (Squamous Cell Carcinoma)、泌尿上皮細胞癌 (Urothelial Carcinoma)
- ◆ SOX10：周邊神經髓鞘腫瘤 (Peripheral Nerve Sheath Tumor)、黑色素瘤 (Melanoma)

依照疾病搜尋

Build Panel Saved Cases >
Diagnoses Antibodies

1. 輸入疾病名

GIST

Results

2. 點選疾病至選單

- Gastrointestinal stromal tumor (GIST)**
Stromal Tumor, Gastrointestinal, Benign; Gastrointestinal Stromal Tumor, Neurofibromatosis Associated; Stromal Sarcoma, Gastrointestinal; Gist, Metastatic; Stromal Tumor, Epithelioid, Gastrointestinal; Stromal Tumor, Extragastrointestinal; Gastrointestinal Stromal Tumor (GIST); Gastrointestinal Stromal Tumor (GIST), Small Intestine; Gastrointestinal Stromal Tumor, Stomach

Selected x Clear

- Gastrointestinal stromal tumor (GIST)**
Stromal Tumor, Gastrointestinal, Benign; Gastrointestinal Stromal Tumor, Neurofibromatosis Associated; Stromal Sarcoma, Gastrointestinal; Gist, Metastatic; Stromal Tumor, Extragastrointestinal; Gastrointestinal Stromal Tumor (GIST); Gastrointestinal Stromal Tumor (GIST), Small Intestine; Gastrointestinal Stromal Tumor, Stomach

Build Panel
Diagnoses Antibodies

3. 輸入欲比較的疾病

Leio

Results

4. 點選疾病至選單

- Leiomyosarcoma, NOS**
Leiomyosarcoma, Metastatic; Leiomyosarcoma, Pleomorphic; Leiomyosarcoma, Low Grade; Leiomyosarcoma, Uterine; Leiomyosarcoma, Epithelioid, With Clear Cells, Uterine; Leiomyosarcoma, NOS
- PEComas**
Lymphangioliomyomatosis
- Smooth muscle tumors**
Leiomyoma, Atypical; Leiomyoma, Epithelioid; Leiomyoma; Leiomyosarcoma, Pleomorphic; Leiomyosarcoma, Low Grade; Leiomyoma, Bizarre; Leiomyosarcoma, Epithelioid; Leiomyosarcoma, NOS

Selected x Clear

- Gastrointestinal stromal tumor (GIST)**
Stromal Tumor, Gastrointestinal, Benign; Gastrointestinal Stromal Tumor, Neurofibromatosis Associated; Stromal Sarcoma, Gastrointestinal; Gist, Metastatic; Stromal Tumor, Epithelioid, Gastrointestinal; Stromal Tumor, Extragastrointestinal; Gastrointestinal Stromal Tumor (GIST); Gastrointestinal Stromal Tumor (GIST), Small Intestine; Gastrointestinal Stromal Tumor, Stomach
- Leiomyosarcoma, NOS**
Leiomyosarcoma, Metastatic; Leiomyosarcoma, Pleomorphic; Leiomyosarcoma, Low Grade; Leiomyosarcoma, Epithelioid; Leiomyosarcoma, Uterine; Leiomyosarcoma, Epithelioid, With Clear Cells, Uterine; Leiomyosarcoma, NOS

5. 點選 build panel

Build Panel >

推薦抗體

1. 點選展開

2. 點選save

+ | Suggested Panel

▶ Save Panel for Analysis

▶ Return

- | Suggested Panel

	Gastrointestinal Stromal Tumor (GIST) ⓘ	Leiomyosarcoma, NOS ⓘ
<p>Set Sensitivity: ⓘ <input checked="" type="radio"/> 1 <input type="radio"/> 2 <input type="radio"/> 3</p> <p>Set Min Refs: ⓘ <input type="radio"/> All <input checked="" type="radio"/> >1 <input type="radio"/> >5</p> <p>Control Images</p>		
<p>DOG1</p> <p>▶ Exclude this Antibody</p> <p>▶ View References (8)</p>	<p><input checked="" type="radio"/></p> <p>• 93% Positive</p> <p>• 2,558 Cases</p>	<p><input type="radio"/></p> <p>• 0% Positive</p> <p>• 434 Cases</p>
<p>Desmin</p> <p>▶ Exclude this Antibody</p> <p>▶ View References (104)</p>	<p><input type="radio"/></p> <p>• 8% Positive</p> <p>• 3,764 Cases</p> <p>• Cytoplasm</p>	<p><input checked="" type="radio"/></p> <p>• 70% Positive</p> <p>• 796 Cases</p> <p>• Cytoplasm</p>
<p>CD117</p> <p>▶ Exclude this Antibody</p> <p>▶ View References (75)</p>	<p><input checked="" type="radio"/></p> <p>• 93% Positive</p> <p>• 7,428 Cases</p>	<p><input type="radio"/></p> <p>• 3% Positive</p> <p>• 618 Cases</p>

Analyze Results

ImmunoQuery®

[Build Panel](#) [Learn](#)

[Help/Support](#) [Settings](#) [Logout](#)

1. 點選展開

Build Panel

ImmunoQuery®

[Build Panel](#) [Learn](#)

Saved Cases >

[Diagnoses](#) [Antibodies](#)

Search for diagnosis group

Saved Cases

Recent

+ Leiomysarcoma,

+ Gastrointestinal st

Date

- Today
- This Week
- Last 30 Days
- Last 90 Days
- All

3
3
5
11
12

12-Jul-16

Gastrointestinal stromal tumor (GIST); Leiomyosarcoma, NOS
Desmin; DOG1

Sensitivity: 1; Minimum Refs: > 1

> View Panel > Analyze Results  Delete

2. 點選分析結果

12-Jul-16

Gastrointestinal stromal tumor (GIST); Leiomyosarcoma, NOS
Desmin; DOG1

Sensitivity: 1; Minimum Refs: > 1

> View Panel > Analyze Results  Delete

11-Jul-16

Gastrointestinal stromal tumor (GIST); Leiomyosarcoma, NOS
Desmin; DOG1

Sensitivity: 1; Minimum Refs: > 1

> View Panel > Analyze Results  Delete

× Clear

es in the search box on the left.
ems for your panel.

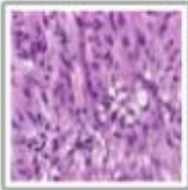
Build Panel >

Learn about a Diagnosis Group

GASTROINTESTINAL STROMAL TUMOR (GIST)

Antibody Availability: ⊗ Not Available in Lab Inventory

H&E Image



Discrete Diagnosis Group

- Stromal Tumor, Gastrointestinal, Benign
- Gastrointestinal Stromal Tumor, Neurofibromatosis Associated
- Stromal Sarcoma, Gastrointestinal
- Gist, Metastatic
- Stromal Tumor, Epithelioid, Gastrointestinal
- Stromal Tumor, Extragastrointestinal
- Gastrointestinal Stromal Tumor (GIST)
- Gastrointestinal Stromal Tumor (GIST), Small Intestine
- Gastrointestinal Stromal Tumor, Stomach

Selected Staining Examples:

Sort: ABC | **Positivity**



CD117

- 93% Positive
- 7,428 Cases



CD34

- 70% Positive
- 4,698 Cases
- Membrane

All Antibodies:

Sort: ABC | **Positivity**

Antibody	Staining Pattern	Pos	Cases	Pitfalls	^
CD138	Cytoplasm and membrane	100%	4		
⊗ Neatin	Cytoplasm	99%	177		

All Articles (132)

Date Published: 2012

Author(s): Aung PP, Sarlomo-Rikala M, Lasota J, Lai JP, Wang ZF, Miettinen M

Article: [KBA62 and PNL2: 2 new melanoma markers-immunohistochemical analysis of 1563 tumors including metastatic, desmoplastic, and mucosal melanomas and their mimics](#)

Publication: Am J Surg Pathol

Date Published: 2012

Author(s): Gao C, Guo WJ, Wang AY

Article: [Significance of decreased apoptosis, role of Bid expression and Bcl-XI/Bid ratio in human jejunal stromal tumors](#)

Publication: APMIS

Date Published: 2012

Author(s): Miettinen M, Rikala MS, Rys J, Lasota J, Wang ZF

Article: [Vascular endothelial growth factor receptor 2 as a marker for malignant vascular tumors and mesothelioma: an immunohistochemical study of 262 vascular endothelial and 1640 nonvascular tumors](#)

Publication: Am J Surg Pathol

Date Published: 2012


Author(s): Lopes LF, Bacchi CE

Article: [Cytokeratin expression in gastrointestinal stromal tumor: a clinicopathologic and immunohistochemical study of 687 cases](#)

Publication: Appl Immunohistochem Mol Morphol

Learn about an Antibody Group

Desmin

Tissue Image	Clones	Company Of Origin
	ZC18	Zymed, San Francisco, CA
	DE-R-11	DAKO,CARPINTERIA,CA
	DE-U-10	
	DE5	DAKO
	DESMIN	BIOGENEX
	M760	DAKO
	D33	DAKO,CARPINTERIA,CA

Top Diagnosis Groups with this Antibody Staining

ACR MYXOINF FIBROB S	DES SM RND CELL TUM
MESOTHELI LYMPHOHIST	RHABDOMYOSARCOMA
SERTOLI CELL TUMOR	SKELET MUSCLE TUMORS
MESOTHELIA BENIGN	Normal Skeletal Muscle

All Articles (531)

Date Published: 2012

Author(s): Xu C, Liu YL, Yu HY, Hou YY, Lu SH, Zhao LJ, Zhou Y, Shi Y, Tan YS, Zhu XZ

Article: [Synchronous and metachronous multiple gastrointestinal stromal tumors](#)

Publication: Histol Histopathol

Date Published: 2012

Author(s): Kostka R, Gürlich R, Koldová L

Article: [Gastrointestinal stromal tumors \(GIST\): a single center experience](#)

Publication: Acta Chir Belg

Date Published: 2012

Author(s): Tanaka M, Kato K, Gomi K, Yoshida M, Niwa T, Aida N, Kigasawa H, Ohama Y, Tanaka Y

Article: [NUT midline carcinoma: report of 2 cases suggestive of pulmonary origin](#)

Publication: Am J Surg Pathol

Date Published: 2012

Author(s): Herwig MC, Wells JR, Grossniklaus HE

Article: [Conjunctival stromal tumor: report of 4 cases](#)

Publication: Ophthalmology

Date Published: 2012

Author(s): Terada, T

Article: [An Immunohistochemical Study of Adenomatoid Tumors of the Uterus and Fallopian Tube](#)